

Volume I- Case Incident File
File 22 23
Medical Examiners Reports
08/11/81

5
2

WALSH, Adam

ML-130-81

Indian River County

8-11-81

DEATH INVESTIGATION AND PRELIMINARY AUTOPSY EXAMINATION

At approximately 8:45 P.M., August 10, 1981, I received a telephone call from the Indian River County Sheriff's Office informing me that a head of a young boy was found in the canal west of town, close to the Florida Turnpike. The head allegedly was found by some fishermen who reported the incident to the Florida Highway Patrol. The Homicide Investigator in this case is Don Coleman. At 2:00 A.M., on 8-11-81, I received a telephone call from the Nursing Supervisor in the Indian River Memorial Hospital informing me that the police from Hollywood, Florida would like to view the head. I proceeded to the Autopsy Room and the police officers from Hollywood, Florida, identified themselves as follows: Detective Gibbons, Detective Ron Young, and Detective Dennis Naylor. Also present at our investigation and examination are Homicide Investigators Sid Dubose and Don Coleman of the Indian River County Sheriff's Office. It was noted in the morgue entry log that the head was signed in at 1:30 A.M.

GROSS EXAMINATION: The specimen consists of a head and a portion of the neck. Extensive cutting and chopping wounds are observed posteriorly from ear-to-ear with at least two parallel wounds being separated by a 1.5 cm. loose strip of skin and subcutaneous fat. The cutting wounds show sharp margins with no tearing or undermining. Cutting wounds also extend on the left side below the ear to within 5 cm. to the corner of the mouth. Another cutting wound extends below the right ear to within 2.3 cm. to the corner of the mouth. A separate 1 cm. cut is noted on the helix of the left ear. The soft tissues of the neck are torn into multiple pieces by apparent cutting wounds exposing one of the cervical vertebra, the body of which appears to be transversely sectioned. Also observed is a clean slicing cutting wound which involves the right inferior posterior occipital skull exposing the dura for a diameter of 2.5 cm. The opposite left occipital bone shows a parallel slicing cut in the same plane as observed in the right occipital bone. This differs from the changes in the right occipital bone in that the bone has not been completely severed and the dura is not exposed.

The hair is sandy brown in color and is easily removed from the scalp. Some of the hair is given to the investigating officers from Hollywood. There is total slippage of skin over the surface of the entire head and face. No evidence of mutilation is noted over the scalp or face. The eyes with opaque cornea are bulging, and somewhat protuberant, probably secondary to gas formation in the orbital fat. Extensive putrefaction with a foul-smelling odor is present. The mandible is examined and it is found to be partially exposed from extensive cutting and chopping wounds involving the neck. A fracture is present in the main body of the right mandible, and two separate fractures are present in the body of the left mandible. The mandible appears to be completely disarticulated from the skull. It is freely movable in the exposed wound.

The teeth are then examined. The upper right incisor is missing and an erupting tooth can be palpated in its place. Four upper teeth are present on the right side lateral to the missing right upper incisor. Five teeth are intact and present in the upper left side. The teeth in the lower jaw are then examined and all ten teeth are present, five on each side. An apparent amalgam dental filling is noted on the buccal side of the last lower left molar. This amalgam filling is confirmed by x-ray.

Multiple portable x-rays are taken which will be interpreted by a radiologist. They confirm the presence of the amalgam filling in the lower left last molar. Further examination of the x-rays reveals the cranial cavity to be filled by gas, probably accounting for the head floating to the surface.


At approximately 11:00 A.M., August 11, 1981, Lieutenant R. Hynds of the Hollywood Detective Division brought me the results of the dental records on Adam Walsh, a six year old male child. The dentist is Marshall Berger, D.D.S. (1-966-1002) of Hollywood, Florida. His records reveal an amalgam filling on the buccal side of the last lower left deciduous molar, corresponding to the finding in the decapitated head.

In addition, the head is identified as Adam Walsh by a close family friend, John Monahan, in the presence of Lieutenant Hynds. The identification and dental records confirm that the decapitated head is Adam Walsh, a six year old missing child from Hollywood, Florida.

Shortly after noon on August 11, 1981, I spoke with Dr. Ron Wright, Broward County Medical Examiner, who agreed to accept and complete the examination on the decapitated head of Adam Walsh. Accordingly, the specimen was packed in ice and given to Investigator Ronald Young to be flown that afternoon to the Broward County Medical Examiner's Office.

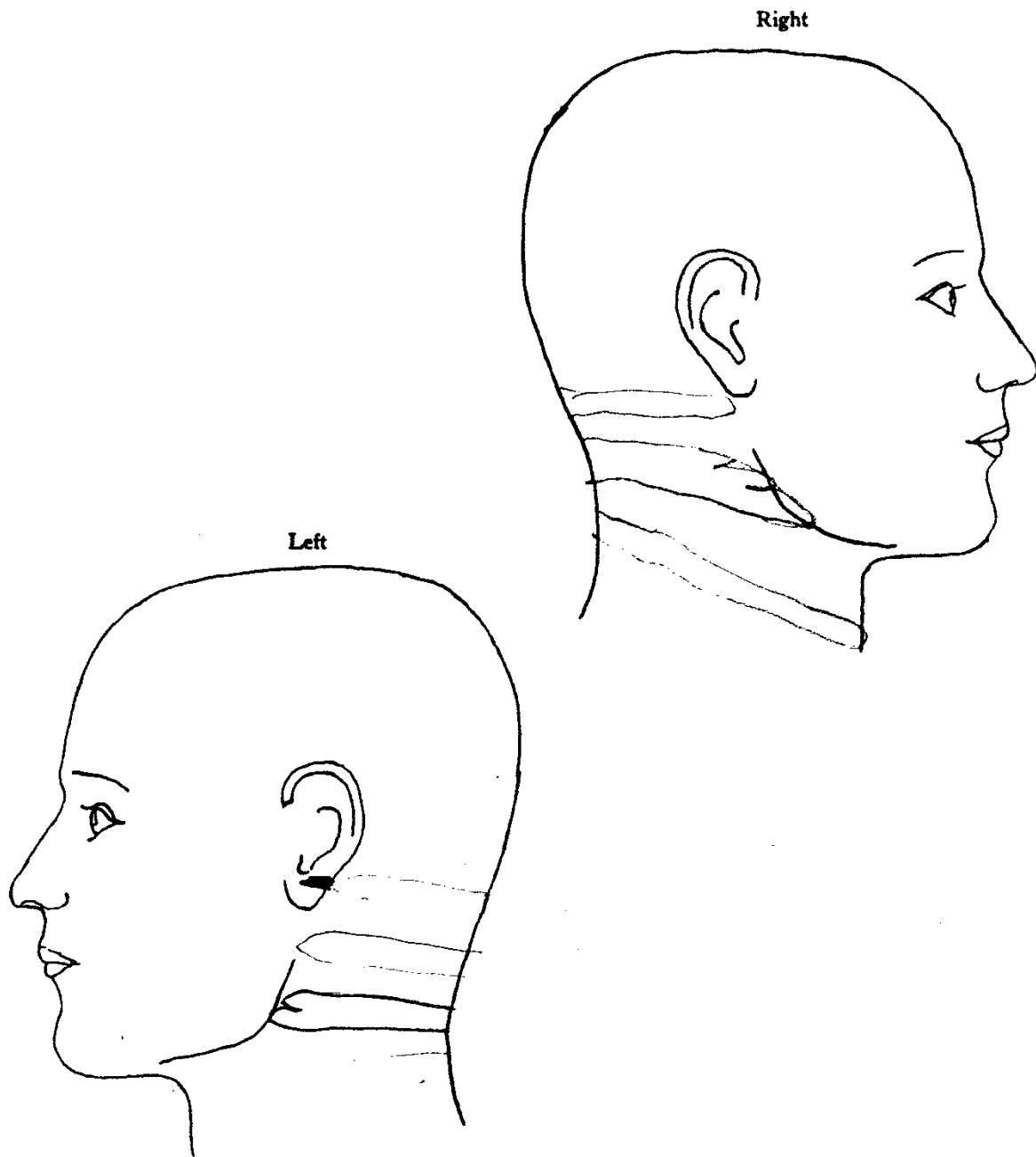
PRELIMINARY AUTOPSY FINDINGS

1. DECAPITATED HEAD SECONDARY TO CUTTING AND CHOPPING WOUNDS.
2. MANNER OF DEATH-HOMICIDE.


Franklin H. Cox, M.D.
Associate Medical Examiner

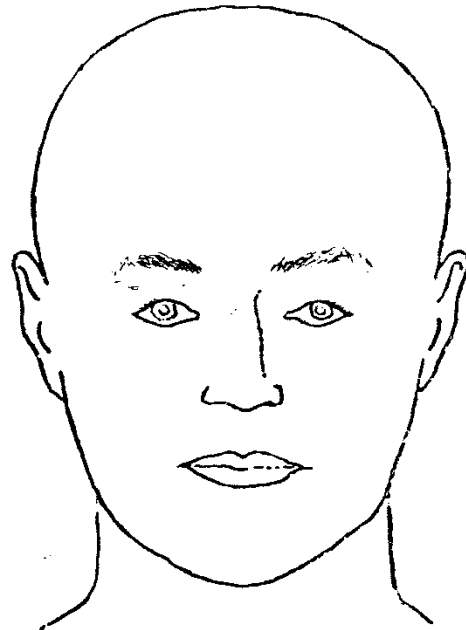
District Nineteen, State of Florida

BODY DIAGRAM—HEAD



Decedent's Name Walsh, Adam
Examined _____
By _____ Date 8/11/81

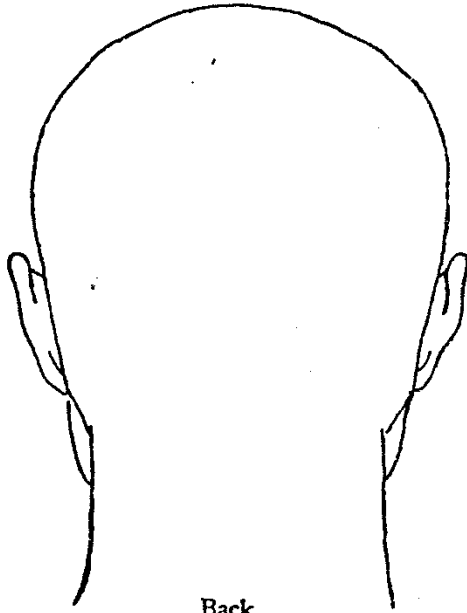
BODY DIAGRAM-HEAD



int
left
Kand

periculum OK
mine

Front



Back

Decedent's Name Walsh Adam

Examined

By _____

Date 8/11/81

**SUPPLEMENT REPORT
HOLLYWOOD POLICE DEPARTMENT**

1. ARRESTEE, COMPLAINANT, DRIVER #1, VICTIM
WALSH, ADAM

2. ARREST NO.

3. COMPLAINT NO.
81-56073

<input type="checkbox"/> FORM USED AS CONTINUATION SHEET FOR CURRENT REPORT			<input type="checkbox"/> FORM USED TO REPORT FOLLOWUP INVESTIGATION OR SUPPLEMENTAL INFORMATION		
4. EXTRA COPIES	5. PAGE NO.	6. TRAFFIC CITATION NO.	9. OFFENSE AND CLASSIFICATION HOMICIDE / MURDER/ABDUCTION CHANGED? <input type="checkbox"/> YES		
7. KIND OF REPORT CONTINUED			10. STATUS <input type="checkbox"/> UNFOUNDED	11. MULTIPLE CLEAR-UP? (LIST OTHER COMPLAINT □ YES NOS. IN NARRATIVE) <input type="checkbox"/> NO	
<input type="checkbox"/> OFFENSE <input type="checkbox"/> TRAFFIC ACCIDENT <input type="checkbox"/> ARREST <input type="checkbox"/> FOLLOWUP OR SUPPLEMENTAL			<input type="checkbox"/> CLEARED <input type="checkbox"/> NOT CLEARED		<input type="checkbox"/> YES NOS. IN NARRATIVE <input type="checkbox"/> NO
8. OFFENSE OR CHARGE			12. FURTHER POLICE ACTION & REPORT REQUIRED? <input type="checkbox"/> YES <input type="checkbox"/> NO		13. VALUE OF PROPERTY RECOVERED \$
INSTRUCTIONS FOR FOLLOW-UP OR SUPPLEMENTAL USAGE.			UNDER NARRATIVE, RECORD ALL DEVELOPMENTS IN THE CASE SUBSEQUENT TO LAST REPORT. DESCRIBE AND RECORD VALUE OF ANY PROPERTY RECOVERED. NAMES AND ARREST NUMBERS OF ANY PERSONS ARRESTED. EXPLAIN ANY OFFENSE CLASSIFICATION CHANGE. CLEARLY SHOW DISPOSITION OF RECOVERED PROPERTY AND INVENTORY NUMBER.		

The following is a list of admissions of OTTIS TOOLE's method of murdering ADAM WALSH, vs DR. RONALD WRIGHT's medical findings as to how the victim was murdered.

OTTIS ELWOOD TOOLE STATED:

DR. RONALD WRIGHT'S FINDINGS:

- | | |
|---|---|
| <ol style="list-style-type: none"> 1) OTTIS TOOLE states he placed the child, unconscious, face down to chop his head off. 2) OTTIS TOOLE states he chopped the head off close to the skull. 3) OTTIS admitted to having hit the victim in the face with a closed fist. 4) OTTIS states he choked the child into unconsciousness, and the child never woke. 5) OTTIS stated he chopped the head off in four to five blows. 6) OTTIS admits to using a machete on the victim when chopping off the head. 7) OTTIS stated he used a two hand hold on the machete. 8) OTTIS is right handed. 9) A luminol test was conducted on the interior of the vehicle which OTTIS states he used, with positive results of blood evidence being found in the interior of the vehicle. Blood was found on the front floor where the drivers feet set, blood was found on the floor left rear, and on the floor along the drivers seat. | <ol style="list-style-type: none"> 1) The victim was decapitated laying face down. 2) The victim's head was chopped off close to the skull. 3) The victim received blows to the face around the eyes and had a fracture to his nose. 4) DR. WRIGHT believes the child was dead before the decapitation. 5) DR. WRIGHT's findings are that the head was severed in five blows. 6) DR. WRIGHT'S findings are that the instrument used was probably a machete type tool. 7) DR. WRIGHT advised that the perpetrator had to use two hands on the machete for the necessary force. 8) DR. WRIGHT's findings are that the perpetrator had to be right handed and was probably decapitating the victim from the victim's right side. |
|---|---|

14. DATE/TIME REPRODUCED-SERIAL	15. REPORTING OFFICER	SERIAL	DATE/TIME	16. SUPERV. APPROVING SERIAL	17. REVIEWER
---------------------------------	-----------------------	--------	-----------	------------------------------	--------------

OFFICE OF THE MEDICAL EXAMINER
DISTRICT 17 BROWARD COUNTY FLORIDA
5301 SW 31 AVE FT. LAUDERDALE, FLORIDA 33136
81-1187

Adam Walsh 6 Yr. Anglo Male 0 ft 1 in 8 1
DOB- 14 NOV 1

HOME 2801 McKinley St HOLLYWOOD, BROWARD, FL

DEATH Fl. Turnpk., IND. RIVER, FL
TIME OF DEATH FOUND 6:45 PM 10 AUG 1981 MON

INCIDENT 300 Hollywood MI HOLLYWOOD, BROWARD, FL
LAST SEEN ALIVE 11:00 AM 27 JUL 1981 MON (LSA-F) 14 Da 7 Hr

OTHER INVESTIGATING AGENCY HOLLYWOOD P (81-56073)
SCENE INVEST. SCENE INVEST. SCENE INVEST. D.P. HUGHES

NARRATIVE SUMMARY

269.23.3 EJ

The decapitated head of the deceased was found by two fishermen in a canal located 75 yds. south of the 130 mile marker on the Florida Turnpike. The canal is located on both sides of the turnpike and near the point at which the head was found there is a turnpike bridge where the canal passes under the road. This is a favorite local fishing spot.

The head was found on the East side of the road, near a small bidge. FHP was first notified and they in turn notified the Inian River Sheriff's Office who took the head to Associate Medial Examiner Dr. Cox. He compared the dental records of the deceased with those of the head and made a positive I.D. Upon the suggestion of theis office, Dr. Cox asked Dr. Wright t also examine the head and it was flown back to the Broward Medical Examiners Office by Helicopter accompanied by personnel from the Hollywood Police Department.

D.P. Hughes, Chief Investigator for the BME made a scene visit for the purpose of conducting experiments to try to better establish the time of death.

At this time further investigation continues into trying to answer these questions.

was

CAUSE OF DEATH: ASPHYXIATION

MANNER OF DEATH: Homicide

AUTOPSY 4:00 PM 11 AUG 1981 TUE BY DR. R.K. WRIGHT MD



Laboratories, Inc.

August, 1981

Dr. Ronald Wright
Chief Medical Examiner Broward County, FL
5301 S.W. 31st Avenue
Ft. Lauderdale, FL

Dear Dr. Wright:

The following are results of bacteriological analysis of water samples provided to this laboratory by your office on August 13, 1981. The Property Receipt stated that samples were taken by the Hollywood Police Department between 1035 and 1100 hours on 8/13/81. Samples are in reference to your case number ME-1187, Homicide - Adam Walsh.

Sample number one (1) was taken approximately 500' North and West of the recovery site. Number two(2) was taken at the recovery site and number three (3) was taken approximately 500' South and East of recovery site.

Table with 4 columns: Test Name, #1, #2, #3. Rows include Fecal Coliform, Staphylococci (Coagalase Positive/Negative), Fecal Streptococci, and Total Anaerobes.

* at lease 200 org/100 ml

Fecal Coliform counts are well below state standards (400 org/100 ml) for recreational waters. The count of fecal coliform organisms is usually much higher when any animal matter is decomposed in a body of water. The low count of coagulase positive staphylococci also does not indicate warm-blooded animal remains.

The ratio of fecal coliform to fecal streptococci strongly indicates that the fecal organisms present are not from human intestinal tract but from horses or cows.